



Issue No. 60 - September 2013

SICOT

e-Newsletter



- **In Memoriam**
 - Leonardo Zamudio Villanueva

- **Editorial by Ashok Johari**
 - 34th SICOT Orthopaedic World Congress

- **SICOT Events**
 - 34th SICOT Orthopaedic World Congress - Hyderabad, India

- **SICOT Global Network for Electronic Learning - SIGNAL**
 - Case of the Month

- **Fellowship News**
 - SICOT/Aarhus University Fellowship Report

- **Worldwide News**
 - Total hip replacement for developmental dysplasia of the hip with more than 30% lateral uncoverage of uncemented acetabular components

- **Industry News**
 - Ceramtec

SICOT e-Newsletter

Issue No. 60 - September 2013

In Memoriam

Leonardo Zamudio Villanueva
First Latin American SICOT President
(1926-2013)



Born in Morelia, Michoacán, México, in 1926, Leonardo Zamudio came to be one of the most prestigious doctors in Mexico.

Outstanding in all stages of his life, Leonardo finished his college and medical studies with honours at the Faculty of Medicine, Universidad Autonoma de Mexico and continued his training in Santa Rosa Hospital and Robert B. Green Memorial Hospital in San Antonio, Texas, United States.

Later on, Chief of Service at Escandon Hospital, Conde de Valenciana Hospital and Hospital Español de Mexico.

He authored more than 114 scientific publications in national and international journals. He was also author and editor of several books on orthopaedics and translator of more than 20 books and magazines related to orthopaedics.

His professional life has been long, productive and very successful, with an extensive curriculum. He belonged to 19 National and International Societies and received more than 18 National and International distinctions awarded by the academies and societies with whom he enthusiastically collaborated.

He also ventured into the realms of literature and successfully edited 13 books with poems, humour, love, medical and political anecdotes, making his writing very enjoyable.

As a teacher, he collaborated in pre- and post-graduate studies, with the main universities of Mexico, and inspired great generations of orthopaedic surgeons.

In order to support young orthopaedic surgeons to find where to update their knowledge, he founded and funded the Metropolitan Library of Orthopaedics and Traumatology, which contains a considerable stock of books and worldwide publications.

Again, on behalf of the new generations, as president of XI SLAOT Congress, (Latin American Society of Orthopaedics and Traumatology), he initiated the sponsorship of numerous fellowships for young surgeons, which are still awarded.

In addition to these, he also personally sponsored 52 fellowships, 20 international for countries such as India, England, China, Chile, Bulgaria, Belgium, Serbia, Iran, Spain, Argentina, and also for Mexican nurses and students.

His talents as a great organiser, administrator and for his unique responsibility led to his election to several major positions in national and international societies.

In 1990, due to his active participation in SICOT since 1960, he achieved the presidency, becoming the first Latin-American orthopaedic surgeon to be distinguished with this honorable position, which is of enormous pride for the Latin-American Orthopaedic Community.

During his presidency he paid close attention to a balanced representation of all parts of the world within SICOT especially from the less developed countries. He encouraged the rapprochement, through the scientific congress,

of what was called at that time the East and West countries. He contributed to the development of the SICOT Education Programmes and personally sponsored the Pilar Zamudio Fellowship devoted only to female orthopaedic surgeons. Very humble and human, he would not tolerate conceited behavior.

Over and above his professional successes, as a man of faith and incredible social conscience, he personally assisted world missions to eradicate Polio in the globe, and dedicated many hours of his life to the treatment of Hansonian (leprosy) patients.

A constant reader, creative writer, a lover of cultures and eager student of other languages.

A strong supporter and promoter of SICOT. He believed SICOT's true essence (very different from other international societies) proposed not only science and innovative techniques, but a rich and deep knowledge of real medicine around the world, the great experience of getting to know not only extraordinary doctors but also outstanding humans eager to establish real bridges of understanding and long lasting friendships between them and their countries.

Leonardo Zamudio... a man to remember!

SICOT e-Newsletter

Issue No. 60 - September 2013

Editorial



**34th SICOT Orthopaedic World Congress
Hyderabad, India - 17-19 October 2013**

Ashok Johari
Congress President

It is a matter of pride for us that, for the first time in the 84 years since its inception, SICOT will host its Orthopaedic World Congress in Hyderabad, India, from 17-19 October 2013.

Delegates from 90 countries will converge on Hyderabad.

We have invited 240 eminent speakers from around the world. An intense learning process has been set up covering 10 halls, 4 plenary lectures, 47 Symposia and ICs, 46 free paper sessions, one Best Paper session, 11 focused oral presentation sessions and myriad electronic posters. Needless to say, this will be the foremost academic orthopaedic meeting ever held in India.

The preconference Educational Day on 16 October started at 07:45 with Trauma as its theme. Over 40 invited speakers will guide you on a journey covering basic sciences, upper & lower extremities, spine fractures, paediatric fractures and special considerations in trauma.

The Congress programme starting on 17 October is designed to cover every subspecialty in orthopaedics and trauma, and one hall is more or less dedicated to a major speciality each day. Trauma, paediatrics, spine, sports medicine, information technology, oncology, infections, education & publishing, research, hip, knee, shoulder & elbow, hand, foot & ankle, and so on, are covered in different halls with many invited orthopaedic luminaries as speakers for each session.

There is so much to gain through interaction with the speakers and among delegates. The latest and cutting edge of orthopaedics and trauma would be laid bare for all to savour. The social events, which include the Welcome Buffet and the Indian Night Party, will add to the camaraderie and foster friendships. Besides this, we have a Charity Run/Walk for the athletes amongst you, as well as a Cricket Match (India XI vs. Rest of the World XI) for cricket enthusiasts!

Academic organisations like AAOS, APOA, ARTOF, ASAMI, EBJIS, IFPOS, SIROT, SOFCOT, and WOC will add lustre to the proceedings. Lunch Symposia provide an insight into the industry which will be showcased in the extensive trade exhibition. Please participate and add to the Indian pride.

SICOT Events

34th SICOT Orthopaedic World Congress (Hyderabad OWC 2013) 17-19 October 2013 * Hyderabad, India

- o **Registration**

On-site congress registration opens at 07:00 on Wednesday, 16 October 2013.

- o **Scientific Programme**

The full scientific programme is published on the [SICOT website](#).

Don't miss the **Instructional Courses** held throughout the Congress. [Read more...](#)

- o **Social Programme**

The Inaugural Speaker at the colourful **Opening Ceremony** will be Subroto Bagchi, acclaimed as India's No. 1 best-selling business author. The renowned dancer, Ananda Shankar Jayant, will be performing at the Ceremony. She has been awarded several times by the Government of India and honoured by other countries.

The **Indian Night Party** will be held at the state-of-the-art N Convention and will include a performance by the "Unique Dance Troupe", a Bollywood dance group.

Join us for the entertaining social programme and the chance to experience the rich culture of India![Read more...](#)

- o **Sports Programme**

All aspiring and keen cricket players and enthusiasts are invited to take part in this Cricket Match between India XI and Rest of the World XI! Bats and all necessary equipment are provided.

Join us also for a 5 km run or 2.5 km walk first thing in the morning for a good cause. The funds collected will support a charity for children in India.

Detailed information about the **Cricket Match** to be held on 16 October and the **Charity Run/Walk** on the morning of 19 October can now be found [here](#).

SICOT Global Network for Electronic Learning - SIGNAL

Case of the Month

September 2013

Authors: Shalin Maheshwari, Ratna Maheshwari, John Mukhopadhaya

History

A 25-year-old male patient presents with a two-week-old open fracture of right distal femur treated elsewhere with debridement of the wound and k-wire fixation. The patient had fever with foul smelling wound and copious discharge. Patient had normal distal neurovascular status without any other comorbidities.

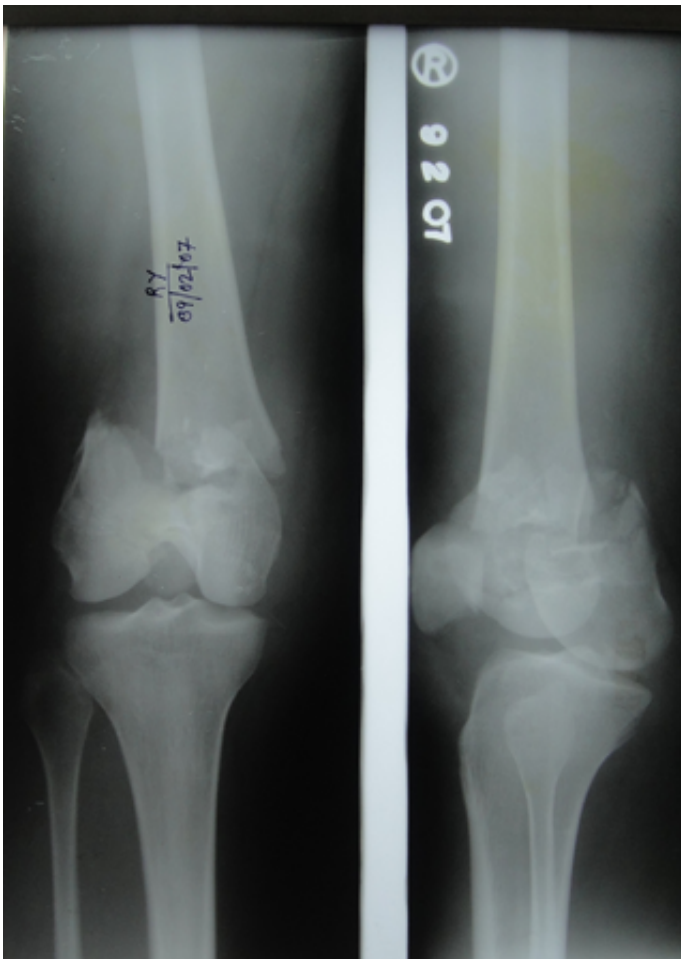


Fig. 1 – Primary injury X-ray

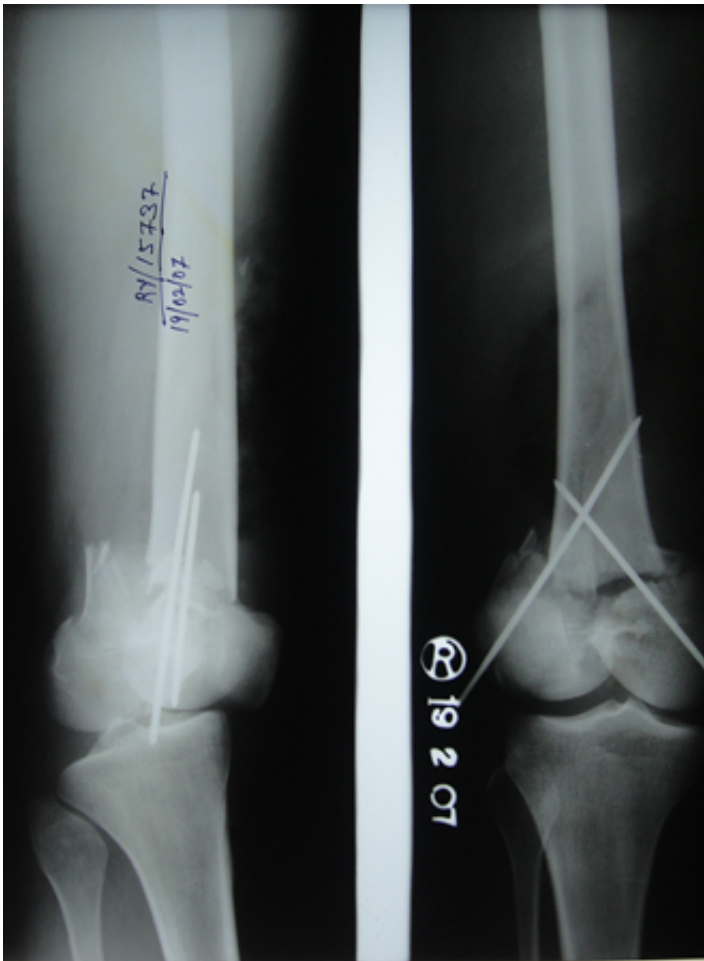

Fig. 2 – X-ray after primary surgery on presentation

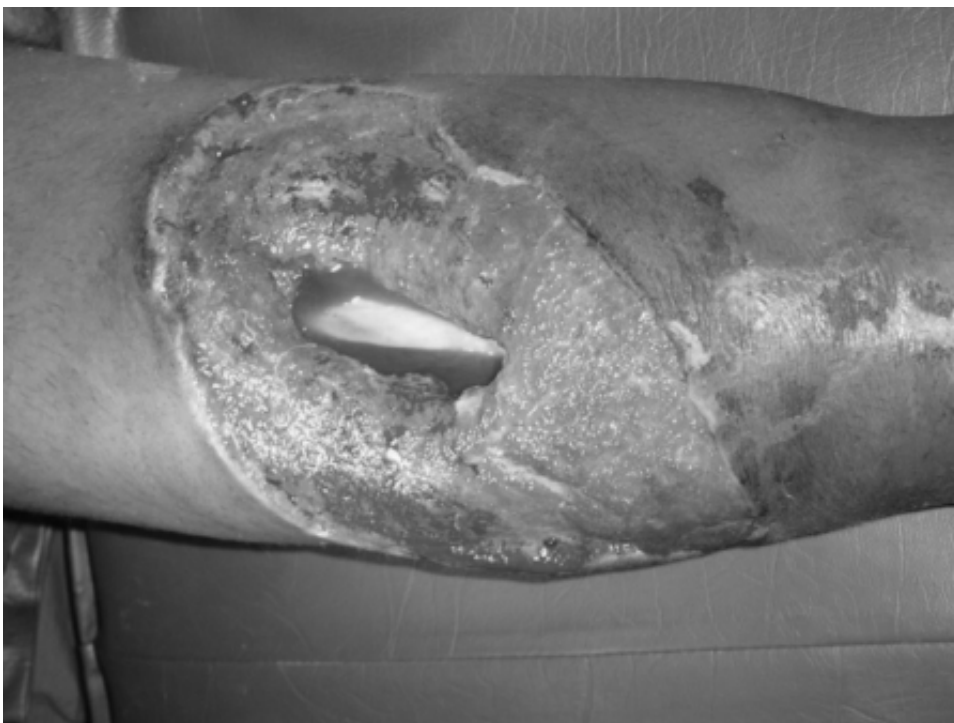


Fig. 3 – Wound condition on presentation

Investigations

Total Leucocyte count, ESR and CRP were elevated. CT scan revealed a distal femoral intercondylar fracture with a Hoffa's fracture of the lateral condyle.

What is the diagnosis for this patient?

[Click here to read more...](#)

[Back to previous section](#)

Diagnosis

Gustilo Anderson Grade III B, AO type 33C1/B3 fracture of right femur.

What would be your next step in the management of this patient?

1. Debridement and external fixation.
2. Debridement and immediate internal fixation.
3. Debridement and delayed internal fixation.

[Click here to read more...](#)

[Back to previous section](#)

Debridement with excision of all necrotic tissues and bone was done with internal fixation of the fracture with a distal femur locking plate and interfragmentary screw for Hoffa's fracture. The resultant gap was 8.5 cm and this was packed with antibiotic impregnated cement beads. The patient required a few more debridements over the next few weeks until it became clean with no evident signs of infection. The overlying skin defect was grafted by a split thickness skin graft.

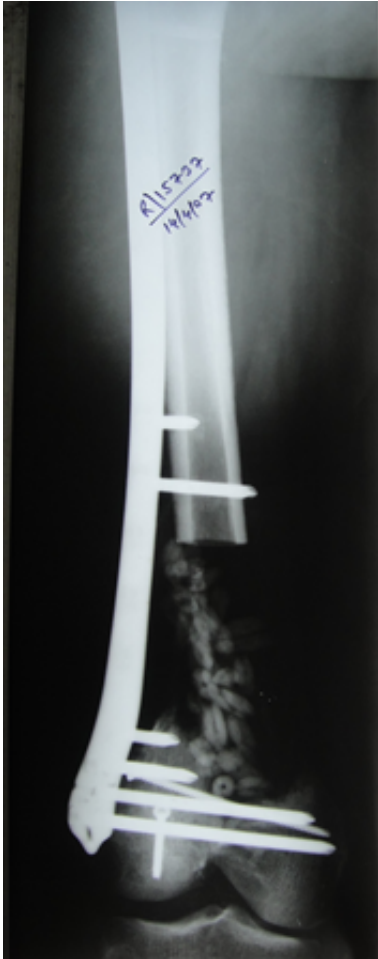

Fig. 4 – Post-op AP x-ray

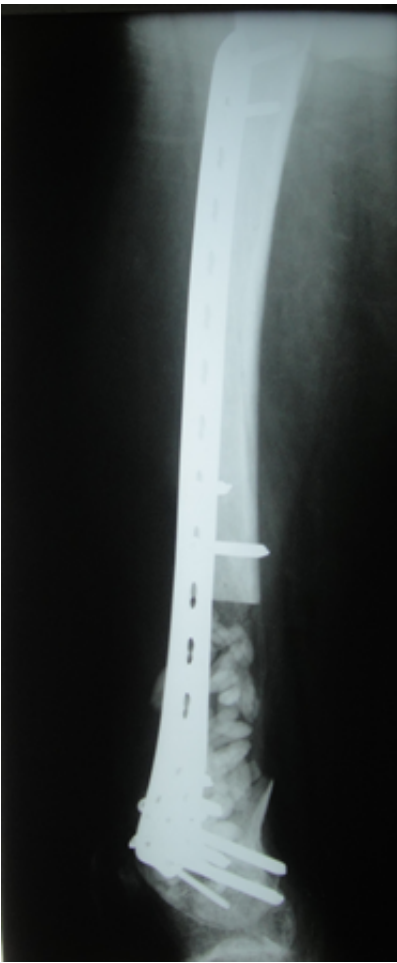

Fig. 5 – Post-op lateral X-ray

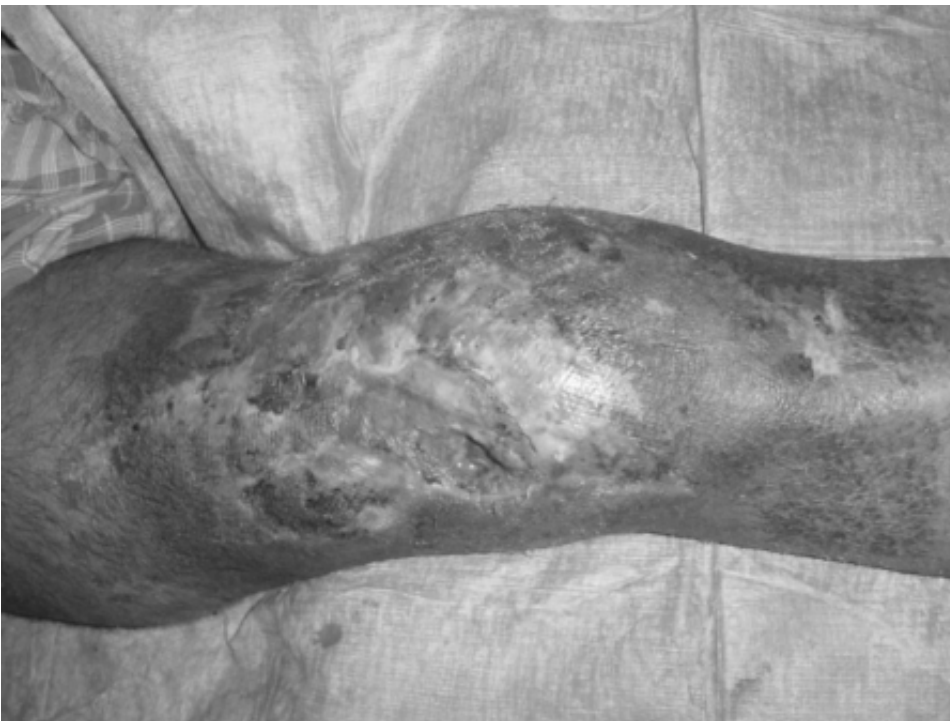

Fig. 6 – Wound status at 3 weeks post-op

How will you manage the juxta-articular large bone defect?

1. Augmentation of fixation with massive autologous graft/allograft.
2. Bone transport over plate.
3. Masquelet technique of induced membranes.

[Click here to read more...](#)

[Back to previous section](#)

Bone transport over plate was planned for the patient and a proximal femur diaphyseal corticotomy was done. Distraction starts on day 7-10 postoperatively at a rate of 0.25 mm four times daily. Gradual distraction was carried out till the bone docked distally after 104 days. During this period patient was allowed to walk full weight bearing and examined every 4 weeks and screened for local signs of infection. At the time of fixator removal autologous cancellous bone grafting was done at the docking site.

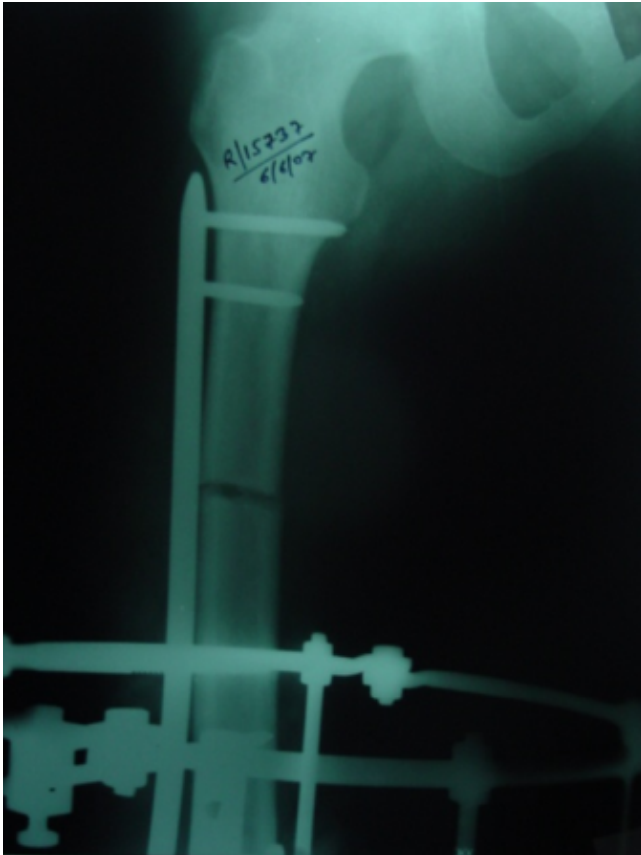


Fig. 7 – Diaphyseal Corticotomy

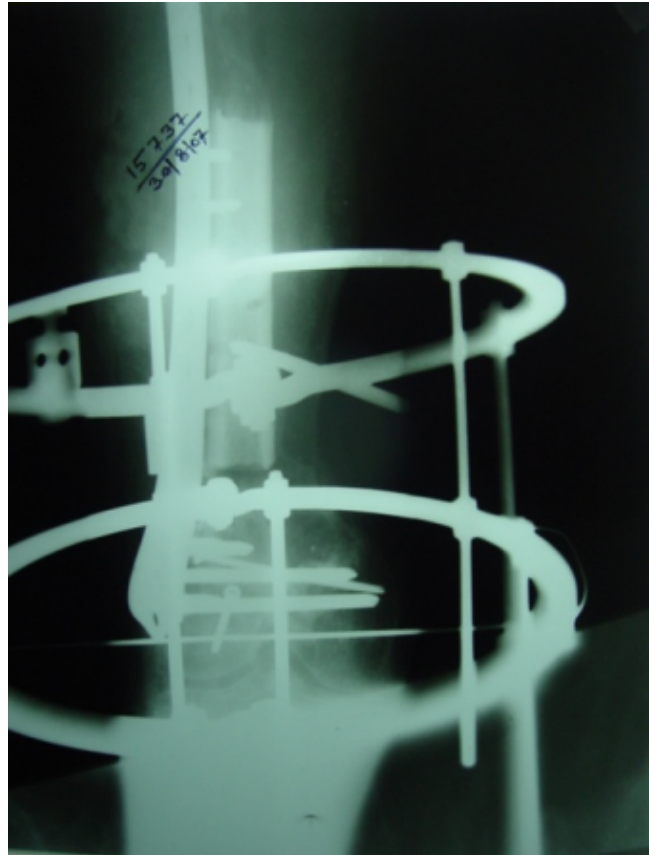


Fig. 8 – Bone transported over 104 days

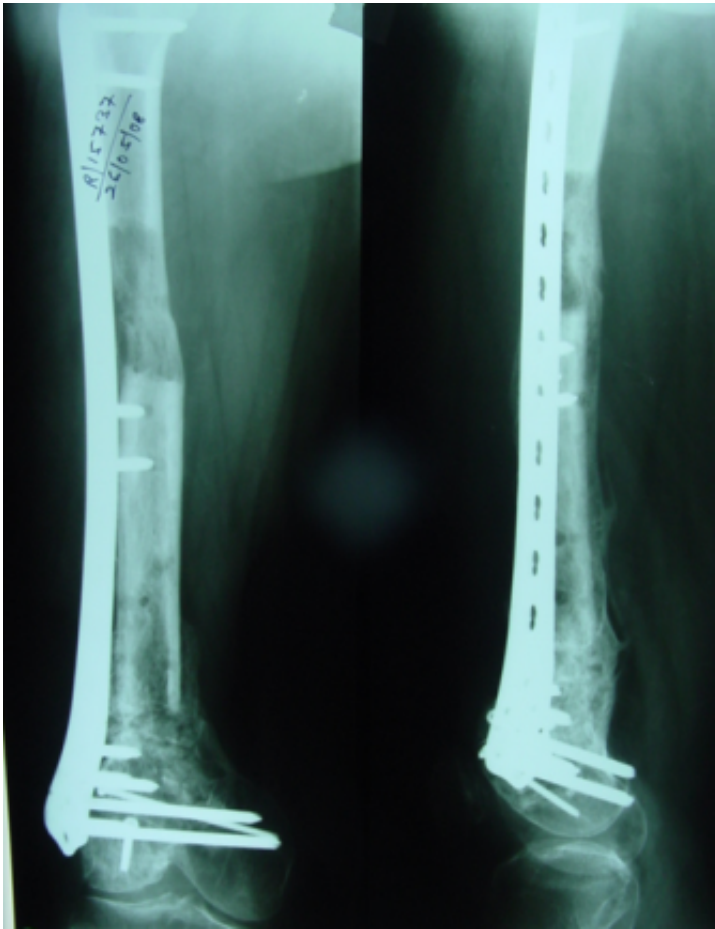


Fig. 9 – Consolidation of regenerate

Indices	Results
Length gained (cm)	7
External fixation period (days)	104
External fixation index (days/cm)	14.86
Consolidation index (days/cm)	37.46

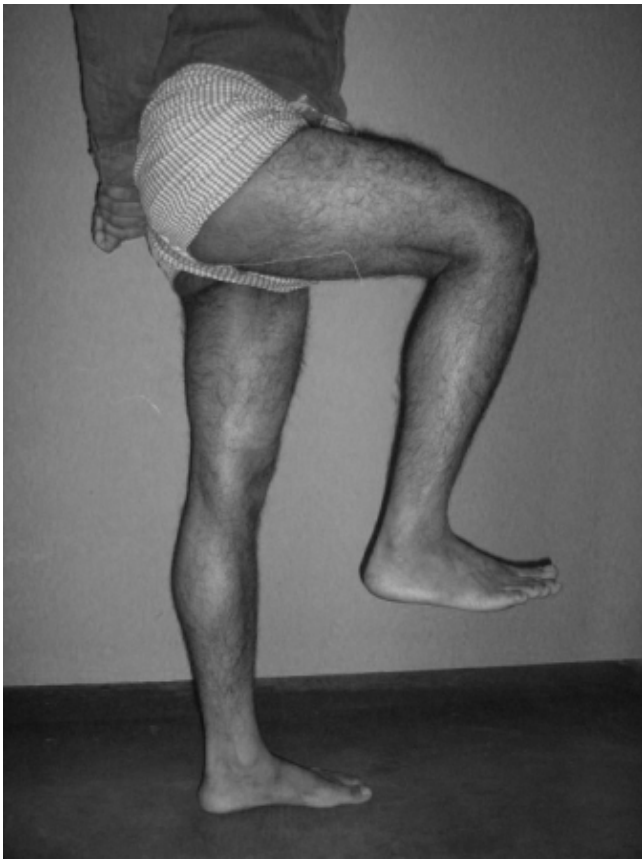

Fig. 10 - Clinical function at 2 years

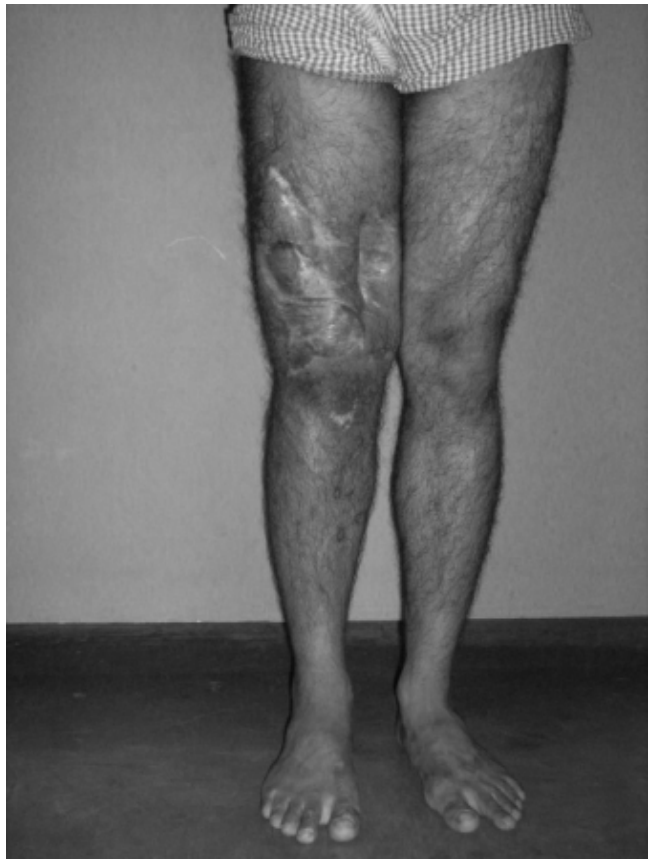

Fig. 11 - Clinical function at 2 years

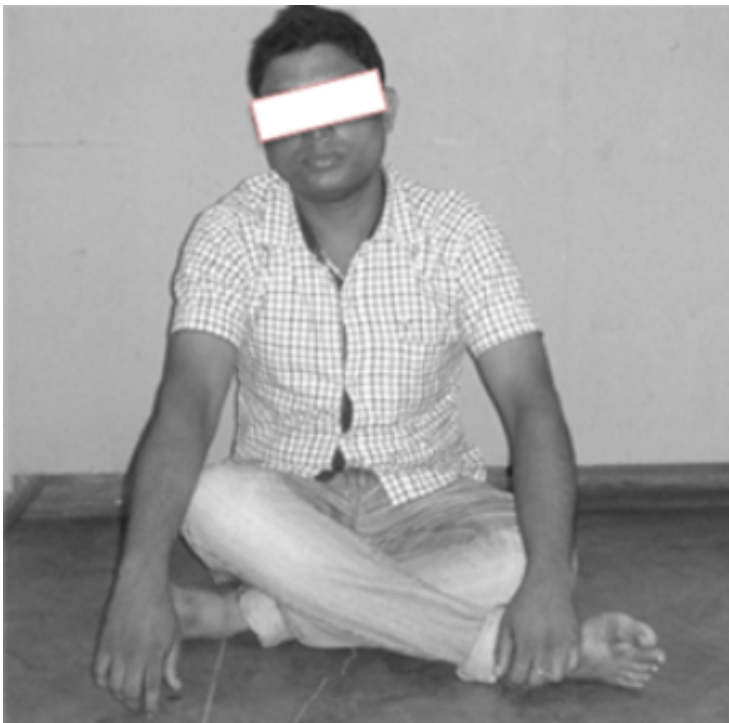

Fig. 12 - Clinical function at 5 years

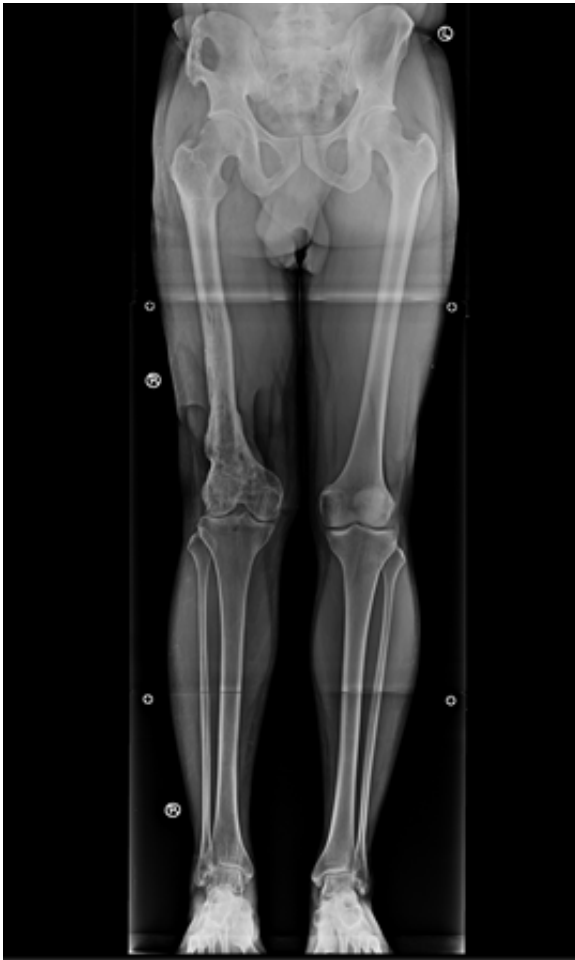

Fig. 13 – Scanogram at 6 years' follow-up

Discussion

Limb lengthening using Ilizarov ring external fixator has been very effective, but the long fixator duration of a bulky external fixator is considered undesirable by many patients. Long duration of soft tissue transfixion can cause recurrent pin tract infections (1) and knee joint stiffness in femoral lengthening (2,3). Attempts have been made to reduce the fixator duration and prevent refracture of the regenerate by lengthening over nail or plate. Submuscular fixation with a locking plate is a recent advance in the treatment of fractures (4). The technique has the biomechanical advantage of angular stability and it preserves the periosteal and endosteal blood supply. Most studies (4,5) have used interlocking nails with an external fixator to achieve lengthening in infected non-union. Locking plates can also be used satisfactorily in this scenario to transport bone and decrease duration of external fixator especially in the juxta-articular fractures with bone defects or bone loss.

References

1. Paley D. Problems, obstacles and complications of limb lengthening by illizarov technique. Clin orthop Relat Res 1990;250:81-104.
2. Rose R. Complications of femoral lenthnrning using the Ilizarov fixator. Internet J orthop Surg 2009;
3. Zhang X, Liu T, Li Z, Peng W. Reconstruction with callus distraction for nonunion with bone loss and leg shortening caused by suppurative osteomyelitis of the femur. J Bone Joint Surg [Br] 2007;89-B:1509-14.
4. Perren SM. Evolution of the internal fixation of long bone fractures: the scientific basis of biological internal fixation: choosing a new balance between stability and biology. J Bone Joint Surg [Br] 2002;84-B:1093-10.
5. Kabata et al. Reconstruction with Distraction Osteogenesis for Juxta-Articular Nonunions with Bone Loss. Journal of Trauma-Injury Infection & Critical Care: June 2005;58-6 :1213-1222

SICOT e-Newsletter

Issue No. 60 - September 2013

Fellowship News



SICOT Aarhus University Fellowship Report

Naveen Tahasildar

SICOT Associate Member - Bangalore, India

With great pleasure, I report my experience as a Spine Fellow at Aarhus University Hospital from 3 January to 1 February 2013.

To begin with, I deeply appreciate the cooperation extended by Ms Lone Sand Simonsen in arranging my visa for Denmark and her constant support during my stay at Aarhus.

I reached Aarhus on 3 January 2013 and moved into the accommodation provided by the hospital. A nasal and oral swab culture for MRSA was taken on the first day, which is a routine for any person entering the operating theatres for the first time. As soon as the results were available, I started attending the theatres. Every working day started with a morning meet, where details about the in-patients were discussed in the presence of all consultants and ward nurses. I had an opportunity to scrub-in as first assistant in most of the cases and I was allowed to actively participate in each surgery. There are 5 consultants in the spine unit, Prof Cody Büniger, Dr Ebbe Hansen, Dr Peter Helmig, Dr Kristian Hoy and Dr Haisheng Li. I was fortunate to operate with each one of them. The hospital, being a referral care centre, deals with wide range of spinal disorders. The volume of cases operated here is really great. During my four-week stay, I participated in 30 odd cases. Spinal deformity, degenerative spine and spinal tumours make a major share of cases operated here. I could assist in a wide range of cases here including scoliosis, spondylolisthesis, cervical spine (anterior & posterior), spinal tumours and spinal trauma. I also followed up the patients in the wards with Dr Li and Dr Ebbe. The nursing and paramedical staff were committed and contributed significantly to the care of the patient. It was a pleasure working with Prof Büniger and he makes every challenging surgery look seemingly simple. I was truly impressed with his technique and surgical outcome. Operating with Dr Hansen was an enjoyable experience and he taught me some great tricks. He is a wonderful surgeon and takes keen interest in explaining every step of the surgery. I also assisted a number of cases with Dr Li and learnt a lot of things from him. He was very friendly and I loved working with him. Dr Helmig involved me in some interesting surgeries and taught me some of his tricks. I assisted Dr Hoy in some cervical anterior surgeries and I loved his technique.



I specifically liked some wonderful techniques used here in operating the challenging revision scoliosis surgeries. In one of the cases, Prof Büniger corrected a decompensated scoliosis by doing a corrective osteotomy through the fusion mass. He plans his osteotomy (to decide on the size and location) on pre-operative images. After removing the posterior elements at the planned wedge, he went by an extra-cavitary approach to expose the vertebral body and completed the wedge by removing vertebral body along the pedicle. We got a good correction and balance in the end.

I was truly amazed at the emphasis that is placed upon basic research at this centre. I attended the research meetings every Friday at the laboratory. Prof Büniger wonderfully coordinated the meeting and supervised the research activities of all the Phd students. I was motivated by the wonderful ideas and passion of the research

students. I also made some great friends. Dr Haolin Sun (spine fellow) was a great companion during the entire fellowship. He helped me a lot during the fellowship. I also thank Effe, Miao and Shallu for making my time in Aarhus a pleasurable experience. The trip to Copenhagen with Ebbe and his family was truly a memorable experience of my life. The whole family was so kind and made me feel warm in their company. I will really miss the wonderful time spent at Aarhus.



Finally, I thank all those at the Teknologisk hostel, who were so friendly. Overall it was a great experience and I would thoroughly recommend this fellowship to my colleagues. I sincerely thank SICOT for providing me with this great opportunity.

Worldwide News

Total hip replacement for developmental dysplasia of the hip with more than 30% lateral undercoverage of uncemented acetabular components

H. Li, Y. Mao, J. K. Oni, K. Dai, and Z. Zhu

Bone and Joint Journal (BJJ) September 2013 95-B:1178-1183.

Abstract:

In developmental dysplasia of the hip (DDH), a bone defect is often observed superior to the acetabulum after the reconstruction at the level of the true acetabulum during total hip replacement (THR). However, the essential amount of uncemented acetabular component coverage required for a satisfactory outcome remains controversial. The purpose of this study was to assess the stability and function of acetabular components with a lack of coverage >30% (31% to 50%). A total of 760 DDH patients underwent THR with acetabular reconstruction at the level of the true floor. Lack of coverage above the acetabular component of >30% occurred in 56 patients. Intra-operatively, autogenous morcellised bone grafts were used to fill the uncovered portion. Other than two screws inserted through the acetabular shell, no additional structural supports were used in these hips. In all, four patients were lost to follow-up. Therefore, 52 patients (52 hips, 41 women and 11 men) with a mean age of 60.1 years (42 to 78) were available for this study at a mean of 4.8 years (3 to 7). There were no instances of prosthesis revision or marked loosening during the follow-up. The Harris hip score improved from a mean of 40.7 points (SD 12.2) pre-operatively to 91.1 (SD 5.0) at the last follow-up. Radiological analysis with medical imaging software allowed us to calculate the extent of the undercoverage in terms of the uncovered arc of the implant as viewed on the anteroposterior pelvic radiograph. From this we propose that up to 17 mm of lateral undercoverage in the presence of a stable initial implantation in the presence of bone autografting, with an inclination angle of the acetabular component between 40° and 55°, is acceptable. This represents undercoverage of ≤50%.

Comment by Ahmed H. Abdelazeem

Young Surgeons Committee member - Cairo, Egypt

What is the maximum accepted uncovered portion of an uncemented acetabular component...? Which type of bone grafting is the most successful for supporting the uncovered cup...?

These two questions are still debatable and carry variable answers. Some surgeons suggested maximum acceptable undercoverage till 20%, others till 30% and others stated till 50%. Particulate impaction grafting versus structural grafting; both have been reported.

In this study, Li and his colleagues, have reported their mid-term results after following up 52 patients (52 hips) for a mean of 4.8 years with different grades of hip dysplasia (mostly Crowe type II and III = 47 patients). All of them had cup undercoverage of 30-50% (most between 30-40%) at cup inclination between 40-55 degrees. He clearly stated his methodology and results, perfectly pointing to his primary and secondary outcomes. He reported excellent mid-term results, using:

1. His previously published impaction grafting technique (Li, Huiwu, Liao Wang, Kerong Dai, and Zhenan Zhu, "Autogenous Impaction Grafting in Total Hip Arthroplasty with Developmental Dysplasia of the Hip", The Journal of Arthroplasty (2012)) to cover the uncovered portion of the cup, reporting a full graft uptake with appearance of trabecular orientation by 12 weeks.
2. Press-fit cups after placing the cup in the true acetabular floor and deepening of the socket, with more support using two screws.
3. Partial weight-bearing as tolerated in the first six weeks postoperatively.

They had a few drawbacks in their paper that they noticed: brief follow-up, using a single prosthesis type which has an arc-deposited Hydroxyapatite, and lastly not finding a uniform method of evaluation of undercoverage for comparison with other papers.

In summary, this paper has proven that lack of coverage between 30-50% for uncemented cup can yield good outcomes, in the presence of initial stability and good grafting techniques.

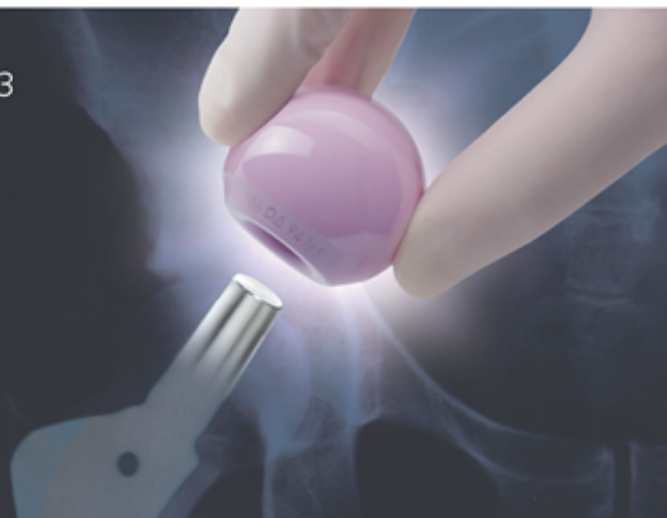

Hip Tribology Symposium

Performance and limitations of state of the art ceramics	<i>Bernard MASSON</i>
Fretting corrosion of modular Interfaces	<i>Daniel MACDONALD</i>
CoC – Justification for its use	<i>Roberto BINAZZI</i>
Ceramic bearings: What does the literature say?	<i>Mandeep DHILLON</i>
Revision of Metal on Metal Hip Replacements Using Ceramic Bearings: Is this the Right Choice to Restore Function?	<i>Raghu RAMAN</i>
Comparison of whole blood metal ion levels in four types of metal-on-metal large head total hip arthroplasty and its clinical consequences	<i>Charles RIVIÈRE</i>
Matched Ceramic-Ceramic versus Ceramic-Polyethylene on the contralateral hip	<i>Philippe HERNIGOU</i>
Polyethylene Wear and Osteolysis After Cementless Total Hip Arthroplasty with Alumina-on-Highly-Cross-Linked Polyethylene in Patients Younger than Thirty Years of Age	<i>Chirag PATEL</i>

Friday, Oct. 18th
14:00–15:30
Room
G.05 & G.06

34th SICOT 2013
Hyderabad



Editorial Department

Editorial Secretary: Hatem Said

Editorial Production: Linda Ridefjord

Editorial Board: Ahmed Abdel Azeem, Syah Bahari, Kamal Bali, Bassel El-Osta, Anthony Hall, Shalin Maheshwari, Maximilian Rudert

Rue Washington 40-b.9, 1050 Brussels, Belgium

Tel.: +32 2 648 68 23 | Fax: +32 2 649 86 01

E-mail: edsecr@sicot.org | Website: www.sicot.org

Disclaimer: Some of the views and information expressed in this e-Newsletter include external contributors whose views are not necessarily those of SICOT. SICOT is not responsible for the content of any external internet sites.